

*Technical Report***Efficacy of extracorporeal ultrafiltration of ascitic fluid as a treatment of refractory ascites**

Shoichiro Daimon¹, Shuichiro Yasuhara¹, Tsutomu Saga¹, Shuji Tokunaga², Hajime Chikaki³ and Kazushi Dan³

¹Department of Internal Medicine, ²Department of Urology, and ³Division of Blood Purification, Maizuru Kyosai Hospital, Maizuru, Kyoto, Japan

Abstract

Background. Refractory ascites is recognized in patients with various conditions. Although intravenous reinjection of ascitic fluid after its filtration and concentration (IRA) is an effective method of treating this condition, many associated side-effects have been reported. We performed extracorporeal ultrafiltration of ascitic fluid (EUA) to demonstrate the efficacy and advantages of this method of treating refractory ascites. **Methods.** EUA was performed in seven patients with hepatic cirrhosis (3 cases), lupus nephritis, diabetic nephropathy, and carcinomatous peritonitis (2 cases) for a total of 122 sessions. IRA was performed in three of these seven patients for a total of 12 sessions.

Results. The average volumes of ascitic fluid removed by EUA and IRA were 3.94 ± 1.45 litres and 2.87 ± 0.69 litres (mean \pm SD) respectively. Although chills and acute renal failure were recognized as complications of IRA in five and one sessions respectively, the only complication of EUA was severe intra-abdominal haemorrhage, which resolved spontaneously. In spite of rapid and massive removal of ascitic fluid (maximum 2.0 litres per 15 min), significant changes in blood pressure were not noted during EUA. In three patients (hepatic cirrhosis, lupus nephritis, and diabetic nephropathy), *de novo* production of ascitic fluid disappeared. In one patient with hepatic cirrhosis and chronic renal failure on haemodialysis, 67 sessions of EUA have been performed under stable conditions. Three patients (one case of hepatic cirrhosis and two cases of carcinomatous peritonitis) died of their primary diseases.

Conclusions. We conclude that EUA is a useful method for the treatment of massive refractory ascites.

Introduction

Refractory ascites is recognized in patients with conditions such as hepatic cirrhosis, carcinomatous peritonitis, congestive heart failure, and nephrotic syndrome, and in many cases causes discomfort to the patient. The effect of injection of diuretics and albumin is not sufficient and in some cases, repeated paracentesis results in hypotension, acute renal failure, hepatic encephalopathy, or emaciation [1,2]. Intravenous reinjection of ascitic fluid after its filtration and concentration (IRA) is a useful technique to remove ascitic fluid and supply protein simultaneously, with little influence on the systemic circulation, and in some cases the volume of new production of ascitic fluid decreases or disappears. However, despite these advantages, IRA sometimes causes adverse effects such as fever, gastrointestinal bleeding, or disseminated intravascular coagulation (DIC) [3,4].

On the other hand, extracorporeal ultrafiltration of ascitic fluid (EUA), which is a technique to reinject concentrated ascites continuously by using a dialyser and pump for haemodialysis, is another available means of treating refractory ascites which was first reported by Hariprasad *et al.* in 1981 [5]. Adding an insignificant influence on the circulation [6] from EUA, intra-abdominal albumin is reported to backflow to blood [7] and it is possible to perform EUA without the complications that are sometimes encountered with IRA.

We performed EUA for a total of 122 sessions in seven patients with massive ascites, and IRA for 12 sessions in three of the seven patients, and compared the efficacy and complications between them.

Key words: ascites; dialytic ascitic ultrafiltration; intravenous reinfusion of ascites fluid

Subjects and methods

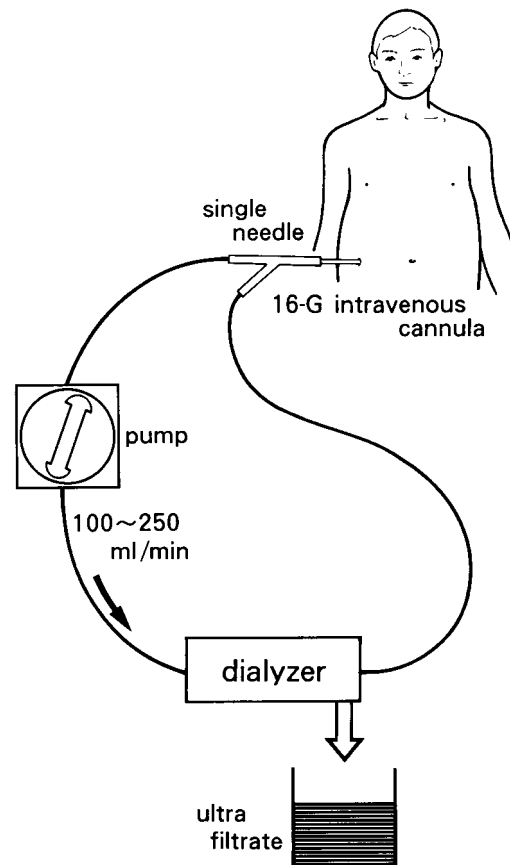
Seven patients with massive ascites were studied. As shown in Table 1, the underlying illnesses were hepatic cirrhosis (cases 1, 4 and 5), lupus nephritis (case 2), diabetic nephropathy (case 3), and carcinomatous peritonitis (cases 6 and 7). A total of 122 sessions of EUA and 12 sessions of IRA were performed. Figure 1 shows an illustration of EUA. A

Correspondence and offprint requests to: Dr Shoichiro Daimon, Department of Internal Medicine, Maizuru Kyosai Hospital, Azahama 1035, Maizuru 625, Kyoto, Japan.

Table 1. Characteristics, complications of EUA and IRA, and outcome

Case	Age	Sex	Cause of ascites	s-TP (g/dL)	s-alb (g/dL)	a-TP (g/dL)	a-alb (g/dL)	Neoplastic cells in ascites	Number of EUA performed	Volume of ascites removed (L/session)	Complications of EUA	Number of IRA performed	Volume of ascites removed (L/session)	Complications of IRA	Outcome
1	57	M	Hepatic cirrhosis	7.0	3.5	1.1	0.6	No	11	2.93 ± 0.50	None	2	unknown	Acute renal failure (1)	Alive
2	24	F	Lupus nephritis	4.7	3.0	0.7	0.4	No	12	4.22 ± 1.09	None	0	—	—	Alive
3	47	M	Diabetic nephropathy	3.3	1.8	0.3	0.1	No	10	3.89 ± 1.12	None	1	3.40	Chill (1)	Alive
4	67	M	Hepatic cirrhosis	6.5	3.3	0.6	0.3	No	67	4.26 ± 1.65	Severe intra-abdominal haemorrhage (1)	9	2.81 ± 0.71	Chill (4)	Alive on HD
5	69	M	Hepatic cirrhosis	6.0	2.9	2.1	0.9	No	9	3.45 ± 0.49	None	0	—	—	Died
6	58	M	Carcinomatous peritonitis	6.4	2.5	3.0	1.3	Yes	3	2.28 ± 0.71	None	0	—	—	Died
7	57	M	Carcinomatous peritonitis	5.6	2.6	3.1	1.6	Yes	10	3.57 ± 1.30	None	0	—	—	Died
Total									122	3.94 ± 1.45	Severe intra-abdominal haemorrhage (1)	12	2.87 ± 0.69	Acute renal failure (1) Chill (5)	

s-TP, serum protein; s-alb, serum albumin; a-TP, ascitic protein; a-alb, ascitic albumin; EUA, extracorporeal ultrafiltration method of ascites; IRA, intravenous reinfusion of ascites after its filtration and concentration; M, male; F, female; HD, haemodialysis.

**Fig. 1.** Extracorporeal ultrafiltration of ascitic fluid.

16-gauge intravenous cannula was introduced to the right or left lumbar region of the patient. The cannula was connected with a Y connector, and ascites was drawn at a rate of 100–250 ml/min with a standard haemodialysis pump (AK-10, Gambro AB, Lund, Sweden) and a cuprophane membrane dialyser (PC-150 or 200, Asahi Medical Co. Tokyo, Japan). A single-needle device was used and the rate of ultrafiltration was controlled by changing the transmembrane pressure; 1.9–8.5 litres (mean ± SD, 3.94 ± 1.45 litres) of ascitic fluid was removed during 120–255 min of EUA. When fibrin-like materials were recognized in the ascites line, 500–1000 units of heparin was injected in the line. In every procedure, EUA was finished when ascitic fluid could not be drawn into the dialyser smoothly. After the end of every procedure the cannula was removed. IRA was performed with AHF-MA and AHF-UN for ultrafiltration and concentration of ascites respectively (Asahi Medical Co. Tokyo, Japan). Concentrated ascitic fluid was reinfused intravenously approximately 2–3 h after its removal from the abdominal cavity.

Representative cases

Patient 1

A 57-year-old man was diagnosed with hepatic cirrhosis and hepatocellular carcinoma at another hospital, and percutaneous alcohol injection was performed twice at an interval of 1 week. Three weeks later

massive ascites developed for which IRA was performed twice. After the IRA, consciousness loss and acute renal failure occurred, and the patient was transferred to our hospital. Although the consciousness loss and acute renal failure improved dramatically with injection of sodium chloride solution alone, massive ascites persisted. A total of 11 sessions of EUA were performed without any complications. The volume of newly generated ascitic fluid decreased gradually, and the ascites finally disappeared.

Patient 2

A 24-year-old girl was transferred to our hospital because of fulminant recurrence of systemic lupus erythematosus with acute renal failure. Because of effective treatment with anti-DNA antibody absorption therapy, double-filtration plasmapheresis, immunosuppressive drugs, methylprednisolone pulse therapy, and oral steroid administration, haemodialysis was discontinued 3 months later. With the increase of urine volume, nephrotic state and massive ascites appeared. Twelve sessions of EUA were performed. After improvement of the nephrotic state, *de novo* production of ascitic fluid was not recognized. In seven of 12 EUA sessions, we could obtain serum protein and albumin levels before and after (next day or 2 days later) which increased after EUA (4.01 ± 0.20 vs 4.47 ± 0.28 g/dl, $P < 0.05$, 2.31 ± 0.64 vs 2.90 ± 0.15 g/dl, $P < 0.05$ respectively). By the injection of ^{99m}Tc -human serum albumin (Poolscinti Injectable, Nihon Mediphsics, Nishinomiya, Japan) into the abdominal cavity just after the EUA, absorption of ascitic albumin to the systemic circulation was demonstrated (Figure 2).

Patient 3

A 47-year-old man was admitted to our hospital because of severe anasarca and nephrotic state due to diabetic nephropathy. Frusemide was administered by

injection or *per os*, without apparent effect, and liver and renal function deteriorated gradually (Figure 3). We discontinued the frusemide, and IRA was performed. Although it was possible to remove 3.4 litres of ascites, severe chill appeared after the injection of concentrated ascites. So we chose EUA for the treatment of anasarca. It was then possible to remove a large volume of ascites without any complications, and liver function improved dramatically. After 10 sessions of EUA, the anasarca improved considerably.

Patient 4

A 67-year-old man was admitted because of massive ascites and leg oedema due to hepatic cirrhosis and chronic renal failure. Initially he was treated with extracorporeal ultrafiltration method (ECUM). Although the anasarca improved after the initiation of ECUM, renal and hepatic function deteriorated acutely. So we discontinued ECUM. Three months later anasarca worsened and he was readmitted to our hospital. This time we chose IRA and EUA for the treatment of anasarca. With the initiation of IRA and EUA, rapid improvement of the anasarca was obtained, but new production of ascitic fluid continued and renal function deteriorated gradually, finally requiring haemodialysis. Up to now, 1 day per week haemodialysis and EUA or IRA are performed simultaneously and 1 day per week haemodialysis alone is performed. We performed nine sessions of IRA because of a lack of haemodialysis pumps. In contrast to the fact that chill appeared after four of nine sessions of IRA, it did not appear in any of 67 sessions of EUA (Figure 4).

Patient 5

A 69-year-old man was admitted to our hospital because of severe anasarca due to hepatic cirrhosis. The patient was treated with injection of diuretics and

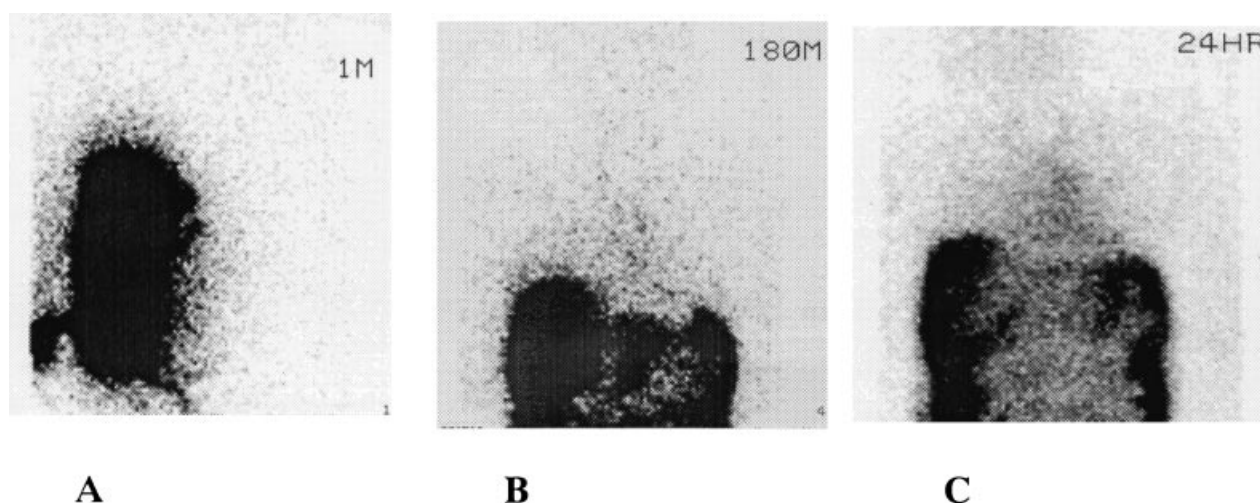


Fig. 2 A–C. Reabsorption of ascitic ^{99m}Tc -HSA from abdominal cavity to systemic circulation in case 2. (A), just after the injection of ^{99m}Tc -HSA; (B), 3 h after the injection of ^{99m}Tc -HSA; (C), 24 h after the injection of ^{99m}Tc -HSA. ^{99m}Tc -HSA, ^{99m}Tc -human serum albumin.

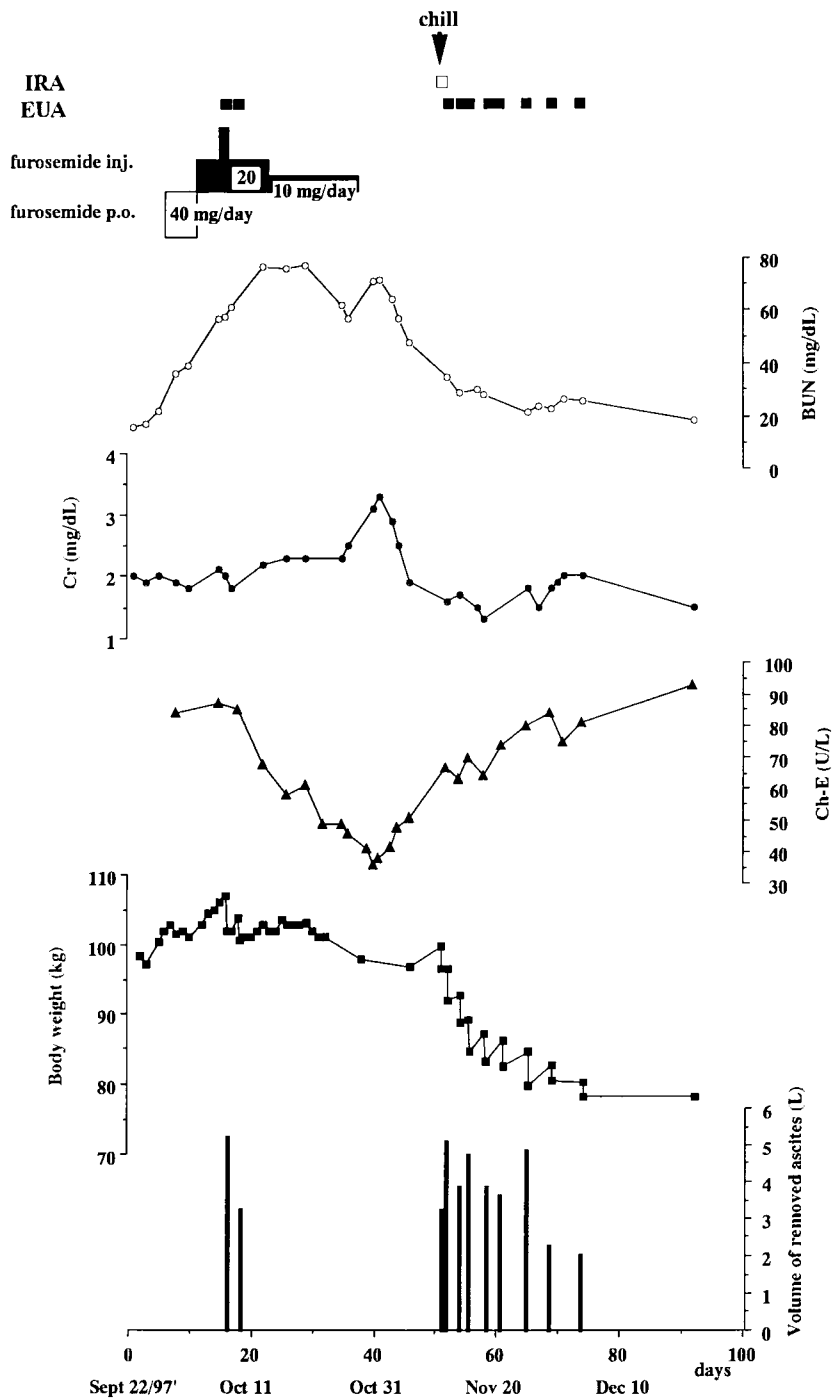


Fig. 3. Clinical course of case 3. IRA, intravenous reinjection of ascitic fluid after its filtration and concentration; EUA, extracorporeal ultrafiltration method of ascites; Cr, serum creatinine; BUN, blood urea nitrogen; Ch-E, cholinesterase.

EUA. Although a total of 31 litres of ascites was removed in nine sessions of EUA without complications, the patient died of liver failure.

Patients 6 and 7

Two patients with massive ascites due to carcinomatous peritonitis were treated with EUA. Although there were no complications of EUA, rapid decrease of the

filtration rate of ascitic fluid, probably due to obstruction of the membrane pores, was recognized and required the use of double dialysers to remove sufficient volumes of ascitic fluid.

Results

Table 1 shows the results of EUA and IRA. EUA was performed for a total of 122 sessions in patients 1–7. The

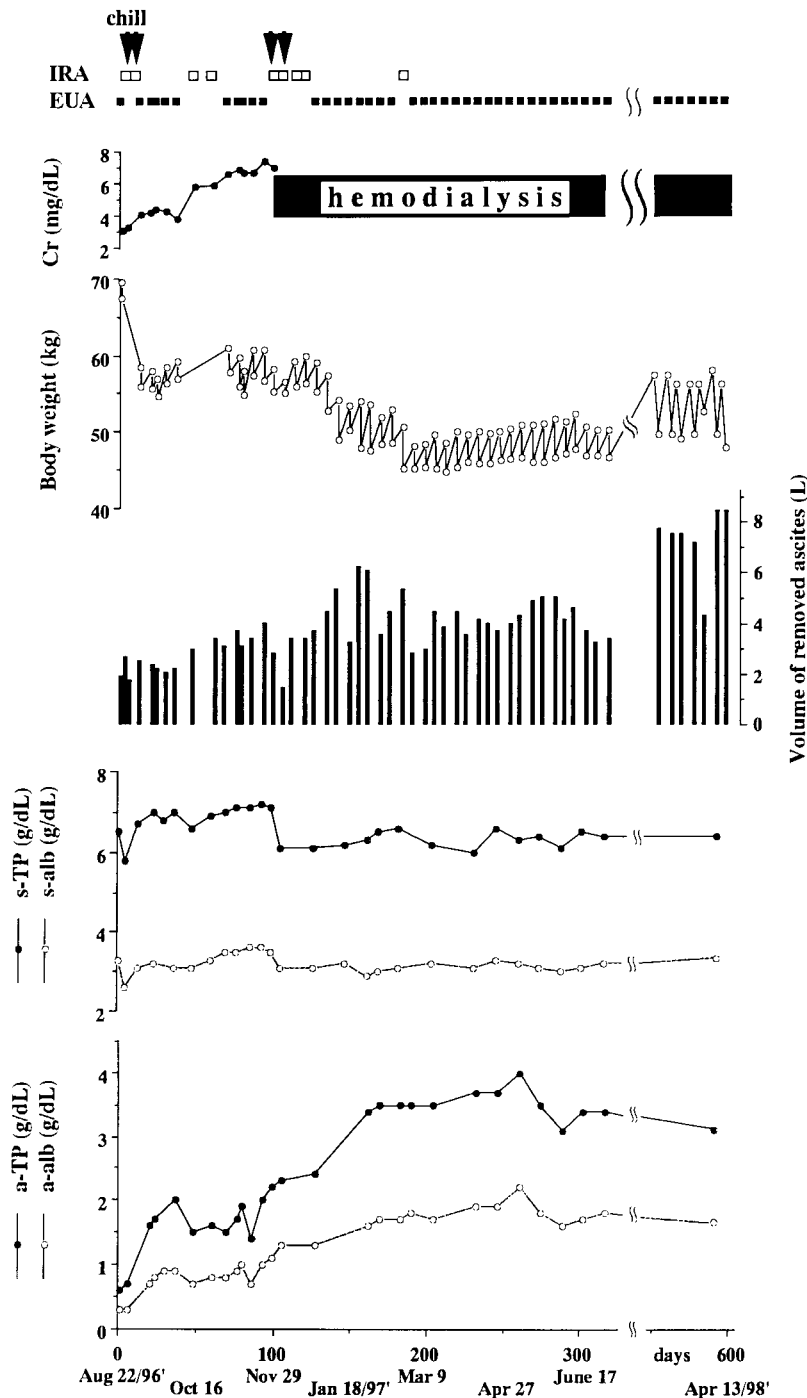


Fig. 4. Clinical course of case 4. IRA, intravenous reinjection of ascitic fluid after its filtration and concentration; EUA, extracorporeal ultrafiltration method of ascites; Cr, serum creatinine; s-TP, serum protein; s-alb, serum albumin; a-TP, ascitic protein; a-alb, ascitic albumin.

only complication recognized with EUA was severe intra-abdominal haemorrhage where the point cannula was introduced. In contrast to the fact that chill appeared in five of 12 sessions of IRA performed in cases 1, 3 and 4, it did not appear in EUA. Although the details were not known because the event occurred prior to admission to our hospital, acute renal failure occurred after performing IRA in case 1. In cases 1, 2 and 3, after repeated EUA new production of ascitic fluid disappeared finally. These

results imply that although it is possible to remove massive ascites by EUA or IRA, EUA causes far fewer complications than IRA.

Discussion

Refractory ascites develops in patients with diseases such as hepatic cirrhosis, carcinomatous peritonitis,

congestive heart failure, or nephrotic syndrome and is difficult to manage in many cases. Although the mechanisms of ascites production are not uniform and not fully understood, in conditions such as hepatic cirrhosis, ascites is produced by the following mechanisms: (i) portal hypertension, (ii) hypoalbuminaemia and decrease of plasma oncotic pressure, (iii) leakage of lymphatic fluid into the abdominal cavity due to post-sinusoidal congestion of blood and an increase of lymphatic fluid production that then exceeds the capacity of the thoracic duct to return excessive lymphatic fluid to the circulation, and (iv) endogeneous factors which include the renin–aldosterone system [8]. Other mechanisms of ascites formation include increased production of ascites from the peritoneum, which is recognized in patients with carcinomatous peritonitis due to ovarian cancer [9].

Injection of diuretics and albumin does not always achieve a sufficient effect, and repeated paracentesis may result in hypotension, acute renal failure, hepatic encephalopathy, or emaciation [1,2]. Although IRA, which was first reported by Britton *et al.* in 1961 [10] has the advantage of preventing hypoproteinaemia, it has been reported that high fever, gastrointestinal bleeding, or DIC may be induced [3,4]. Further, a peritoneovenous shunt was devised by LeVeen *et al.* in 1974 [11,12]. But in addition to the same complications as IRA, this method has the possibility of severe complications, which include obstruction of the shunt tube, ascitic fluid leakage, or septicaemia [12,13]. From the fact that the length of survival and the incidence of complications other than post-operative events are similar between intensive medical management and peritoneovenous shunt [14,15], Bories *et al.* concluded that peritoneovenous shunt is not a desirable method of treating ascites [14].

In 1981 Hariprasad *et al.* reported the new technique, EUA [5], the efficacy of which for the treatment of refractory ascites due to hepatic failure [16], hepatorenal syndrome [17] and congestive heart failure [18] was subsequently reported. We performed EUA in seven patients with massive ascites for a total of 122 sessions and IRA in three of these seven patients for a total of 12 sessions respectively and the advantages or disadvantages of these methods were compared. Although the details were not known because the event occurred in another hospital, in case 1 just after the procedure of IRA, acute renal failure occurred; this is sometimes recognized as a complication of repeated paracentesis which removes large volumes of ascites. It is speculated that in the presence of hepatic cirrhosis with massive ascites, the circulating blood volume is reduced and secondary activation of the renin–angiotensin system is induced. Reduction of intraperitoneal hydrostatic pressure by ascitic drainage will temporarily cause increases in renal blood flow provided that the systemic blood pressure is not reduced, and this change may be beneficial to the systemic circulation.

By doing EUA, different from IRA which removes ascites without any infusion into the abdominal cavity, concentrated protein is administered continuously into the abdominal cavity, and as shown in our case 2,

concentrated protein was reabsorbed into the systemic circulation, making it possible to exert less influence on the systemic circulation and blood pressure compared to IRA. The fact that in the present cases, in spite of rapid removal of ascitic fluid, significant changes in blood pressure were not recognized during the procedure in any of 122 sessions of EUA, supports this assumption. In case 3, liver and renal function deteriorated with the administration of diuretics, probably due to reduction of the systemic circulating volume induced by increased urination, and recovered after discontinuance of diuretic administration. In this case, however, severe anasarca was not improved sufficiently by diuretic administration, but was improved dramatically without any complications by performing repeated EUA. Deterioration of liver and renal function in patients with massive ascites is sometimes encountered with continuous venovenous haemofiltration (CVVH) too.

In case 4, ECUM was performed 3 months before EUA and IRA were initiated. Although anasarca was improved temporarily by ECUM, this resulted in the deterioration of renal and hepatic function. Furthermore, after the requirement of haemodialysis, in spite of stable blood pressure during EUA, only 1 kg of water removal from haemodialysis resulted in the fall of blood pressure. We believe that the removal of fluid from ascites is much more physiological than removal from the systemic circulation, especially in nephrotic patients. But this advantage may be guaranteed in the situation of maintained serum oncotic pressure which may be achieved by reabsorption of protein into the systemic circulation by EUA.

Henriksen *et al.* [19] reported that in the condition of hepatic venous hypertension, not only transvascular escape of albumin, but also the return of it from the abdominal cavity to plasma, has to be taken into consideration. In EUA, hepatic venous hypertension may be recognized only at the beginning of the procedure and hepatic venous hypertension is not the major mechanism of reabsorption of albumin. When concentrated albumin is injected into the abdominal cavity continuously during EUA, a dynamic equilibrium of fluid and albumin between plasma and the abdominal cavity occurs, and this is supposed to be the major mechanism of reabsorption of albumin.

Although it is possible to prevent the decrease of serum oncotic pressure by preparing a peritoneovenous shunt or IRA, as shown by the results of our patients or previously reported cases [3,4], high fever and DIC are frequently recognized complications. Endotoxin and pro-coagulant material derived from peritoneal cells are reported to be the causative factors of high fever or DIC induced by a peritoneovenous shunt [20]. In spite of the procedure of filtration of ascites, IRA causes the same complications as a peritoneovenous shunt. It is speculated that not only the above-mentioned causative factors which cannot be excluded completely by filtration, but also some kinds of cytokines, whose production is reported to increase during haemodialysis by activating monocytes [21,22] may cause these complications. In EUA, it is possible that by injecting concentrated ascites fluid into the abdominal cavity, these causative factors

of high fever or DIC are isolated from the blood stream and contribute to the prevention of these complications. However it is not clear why protein and albumin are reabsorbed from the abdominal cavity and the causative factors of high fever or DIC are not. In case 4, many repeated sessions of EUA are necessary, and although the serum protein level reached a plateau, removal of water from ascites by EUA could not be done smoothly because of extreme elevation of the transmembrane pressure during the latter half of EUA; this was resolved by doing filtration of ascites with AHF-MA before passage through the dialyser. It is considered that by doing repeated EUA with a dialyser, many kinds of factors mentioned above become concentrated in the abdominal cavity and prevent the transmembrane passage of water, making it necessary to use filtration technique occasionally in case many sessions of EUA are required. Although from the standpoint of production of cytokines, use of a cuprophane membrane dialyser may not be suitable [22], the relation between sorts of dialyser membrane and cytokine production is not yet clear.

Although in case 4 *de novo* ascites production continued partly because of oliguria due to chronic renal failure, it is easy to control the so-called 'dry weight' as a haemodialysis patient by EUA compared with IRA, because in the former method it is not necessary to remove fluid from the blood. In this patient, severe intra-abdominal haemorrhage, the only complication of EUA in our report, occurred. We consider that although haemorrhage is a serious complication of EUA, it can be induced by IRA as well. In the previously reported cases treated by EUA, a 14-gauge or 8F Teflon catheter or a standard peritoneal catheter was applied and more than 200 ml/min of ascitic flow was obtained [5,6,18,23,24]. To remove fluid without dialytic effect, it is not necessary to obtain much flow, so we introduced a 16-gauge cannula, which made it possible to obtain an ascitic flow of 100–250 ml/min. To prevent the occurrence of infectious peritonitis, we remove the cannula after every procedure, and no infectious complications occurred.

Although further experience is necessary to confirm the efficacy of EUA, considering the lower frequency of complications, particularly chill, compared with IRA, little influence on the systemic circulation, and simplicity and low cost, we conclude that EUA is an excellent method of treating refractory ascites.

References

- Nelson W III, Rosenbaum JD, Strauss MB. Hyponatremia in hepatic cirrhosis following paracentesis. *J Clin Invest* 1951; 30: 738–744
- Gabuzda GJ Jr, Traeger HS, Davidson CS. Hepatic cirrhosis: effects of sodium chloride administration and restriction of abdominal paracentesis on electrolyte and water balance. *J Clin Invest* 1954; 33: 780–789
- Moult PJA, Parboo SP, Sherlock S. Clinical experience with the Rhone-Poulenc ascites reinfusion apparatus. *Postgrad Med J* 1975; 51: 574–576
- Levy VG, Opolon P, Pauleau N, Caroli J. Treatment of ascites by reinfusion of concentrated peritoneal fluid—review of 318 procedures in 210 patients. *Postgrad Med J* 1975; 51: 564–566
- Hariprasad MK, Paul PK, Eisinger RB, Gary NE, Timins JE, Miller JW. Extracorporeal dialysis of ascites. A new technique. *Arch Intern Med* 1981; 141: 1550–1551
- Raju SF, Achord JL. The effects of dialytic ultrafiltration and peritoneal reinfusion in the management of diuretic resistant ascites. *Am J Gastroenterol* 1984; 79: 308–312
- Hariprasad MK, Timins JE, Eisinger RP, Erb A, Bertrand J. Backflow of albumin from ascites to blood. *Dial Transplant* 1981; 10: 608
- Epstein M. Liver disease. In: Massry SG, Glasscock RJ, ed. *Textbook of Nephrology*. William & Wilkins, Baltimore, 1983; 304–313
- Hirabayashi K, Graham J. Genesis of ascites in ovarian cancer. *Am J Obstet Gynecol* 1970; 106: 492–497
- Britton RC. A new technique for rapid control of cirrhotic ascites. *Arch Surg* 1961; 83: 364–369
- LeVeen HH, Chritoudias G, Moon IP, Luft R, Falk G, Grosberg S. Peritoneo-venous shunting for ascites. *Ann Surg* 1974; 180: 580–591
- LeVeen HH, Wapnick S, Grosberg S, Kinney MJ. Further experience with peritoneo-venous shunt for ascites. *Ann Surg* 1976; 184: 574–581
- Greenlee HB, Stanley MM, Reinhardt GF. Intractable ascites treated with peritoneovenous shunts (LeVeen). A 24–26 month follow-up of results in 52 alcoholic cirrhotics. *Arch Surg* 1981; 116: 518–524
- Bories P, Garcia-Compean D, Michel H *et al*. The treatment of refractory ascites by the LeVeen shunt: a multi-centre controlled trial (57 patients). *J Hepatol* 1986; 3: 212–218
- Stanley MM, Ochi S, Lee KK *et al*. Peritoneovenous shunting as compared with medical treatment in patients with alcoholic cirrhosis and massive ascites. *N Engl J Med* 1989; 321: 1632–1638
- Hwang ER, Richard DO, Sherman A *et al*. Dialytic ascites ultrafiltration in refractory ascites. *Am J Gastroenterol* 1982; 77: 652–654
- Feldman J, Adler AJ, Friedman EA, Berlyne GM. Extracorporeal dialysis of ascites (EAD) in combined hepatic and renal failure. *Trans Am Soc Artif Intern Organs* 1981; 27: 563–565
- Hariprasad MK, Reddy K, Paul PK, Bisinger RP, Raju GS. Ascites ultrafiltration. Treatment for intractable congestive cardiomyopathy. *New York State J Med* 1982; January: 28–29
- Henriksen JH, Parving HH, Christiansen L, Winkler K, Lassen NA. Increased transvascular escape rate of albumin during experimental portal and hepatic venous hypertension in the pig. Relation to findings in patients with cirrhosis of the liver. *Scand J Clin Lab Invest* 1981; 41: 289–299
- Addonizio VP Jr, Fisher CA, Strauss JF III *et al*. Preliminary characterization of the procoagulant material in human ascites. *Surgery* 1987; 101: 753–762
- Lonnemann G, Van der Meer J, Cannon J *et al*. Induction of tumor necrosis factor during extracorporeal blood purification. *N Engl J Med* 1987; 317: 963–964
- Annenkov AY, Stokov AG, Baranova FS. Alterations in mononuclear cell tumor necrosis factor- α (TNF- α) response in patients on long term cuprophane haemodialysis. *Clin Exp Immunol* 1992; 90: 49–55
- Adler AJ, Feldman J, Friedman EA, Berlyne GM. Use of extracorporeal ascites dialysis in combined hepatic and renal failure. *Nephron* 1982; 30: 31–35
- Lai KN, Leung JWC, Swaminathan R, Panesar NS. Treatment of cirrhotic ascites by dialytic ultrafiltration with a hemofilter system. *Blood Purif* 1987; 5: 252–255

Received for publication: 13.1.98

Accepted in revised form: 3.6.98